

# PHILIPS

## Ultrasound

# HeartModel<sup>A.I.</sup>

## Removing the complexity of Live 3D Quantification

Rob Schneider, PhD

### Introduction

Cardiac function can be assessed in several ways using one or several imaging modalities. Ultrasound provides cost-effective, robust capabilities to assess quickly moving structures of the heart without radiation exposure. Typically two dimensional (2D) echocardiographic (echo) images have been used to make measurements such as left ventricle (LV) or left atrium (LA) volume and output, but these measurements rely on making assumptions about three-dimensional (3D) shape based only on what is seen in the two-dimensional (2D) image. Depending on the actual 3D structure and whether or not the 2D image is located appropriately with respect to this structure, these assumptions can significantly impact the measurements. To mitigate some of the issues, measuring chamber volumes from 3D echo has been proposed, but the time and expertise needed to acquire a 3D image and perform 3D measurements has proven to be a barrier to wide scale clinical acceptance. To address these barriers, Philips has created the HeartModel<sup>A.I.</sup> application, which is an efficient and robust method to measure 3D LV volume and ejection fraction (EF) and LA volume.

The HeartModel<sup>A.I.</sup> application is a model-based segmentation algorithm, meaning that it has prior knowledge with regard to the general structural layout of the heart, how the heart location varies within an image, the ways in which the heart shape varies, and the ways in which the heart is imaged using ultrasound. This prior information was incorporated into the model through extensive training using approximately one thousand echo images from a wide variety of heart shapes and sizes, and with varying image quality. This exhaustive training enables the HeartModel<sup>A.I.</sup> application to adapt the model to those hearts typically seen in a clinical scenario. The HeartModel<sup>A.I.</sup> application, however, is not designed to adapt to large structural changes such as those that might be seen in congenital defects, and is also not designed to adapt to particularly odd-shaped hearts, such as those that might exhibit a large aneurysm. For such unusual shapes, a flexible editing interface is provided.

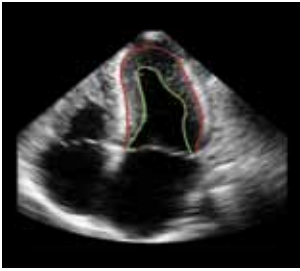


**Figure 1** Cardiac model used in the Philips HeartModel<sup>A.I.</sup> application. The model includes the LV epicardium, LV endocardium (blood-tissue and compacted myocardial borders), LA, RV endocardium, RV epicardium, RA, and attaching arterial and venous structures.

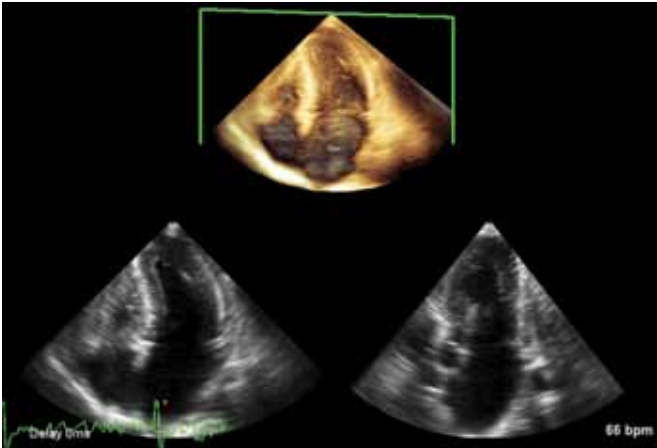
In clinical practice, the LV endocardial border is subjectively defined, and is often located by varying clinicians at different positions within the myocardial tissue. To handle this variation among users, Philips designed HeartModel<sup>A.I.</sup> to detect two endocardial borders. The borders are trained to detect the more robustly recognized inner and outer extents of the myocardial tissue – those being at the blood-tissue interface and at the interface of the compacted myocardium. In segmenting the inner and outer extents of the myocardial tissue (represented by the green and red borders, respectively, in Figure 2), an intermediate location can be more robustly defined by a user in choosing a relative location for a single endocardial border which meets their purposes.

## Image acquisition

HeartModel<sup>AI</sup> has been trained to find the heart in a 3D volume acquired from the standard apical 4-chamber window, with the LV and LA centered along the volume axis. While HeartModel<sup>AI</sup> will perform effectively in images that slightly deviate from this imaging window, large deviations should be avoided as HeartModel<sup>AI</sup> was not trained under these circumstances. The field-of-view of the 3D volume should be made wide enough and deep enough to include the entire LV and LA chamber, but not too much wider or deeper lest the frame rate be degraded. HeartModel<sup>AI</sup> was designed and validated on images where at least 14 of the 17 ASE segments were visible. Images with fewer than 14 segments visible should be avoided for use in the HeartModel<sup>AI</sup> application and for measurement of LV volumes, as the accuracy of the volume would be quite variable with such a large percentage of the chamber wall not visible.



**Figure 2** Dual endocardial border locations at the blood tissue (green) and compacted myocardium (red) interfaces. These borders are segmented automatically by the HeartModel application and used along with user input to generate a single, consistently located endocardial border for volume measurement.



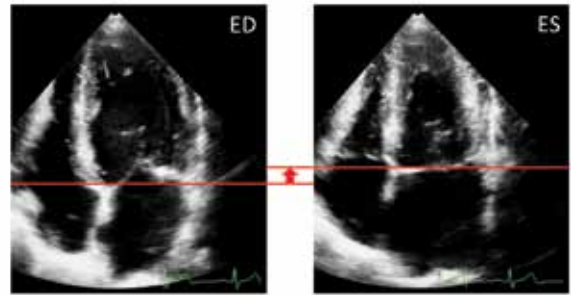
**Figure 3** A 3D volume of the LV and LA acquired from a standard apical 4-chamber window. Notice how the width and depth of the field-of-view do not far exceed the LV and LA, the chambers are centered in the volume, and at least 14 of the 17 ASE segments are visible. This is recommended when using the HeartModel<sup>AI</sup> application to measure the LV and LA.

## Algorithm

### Phase detection

The current HeartModel<sup>AI</sup> application is designed to measure volumes at end-diastole (ED) and end-systole (ES), and so the first step in the algorithm is the ED and ES frame detection. Guidelines from the American Society of Echocardiography and the European Association of Cardiovascular Imaging recommend ED be defined as the first frame after mitral valve closure or the frame where the LV is the largest, and ES be defined as the frame after aortic valve closure or the frame where the LV is smallest<sup>1</sup>. Since the HeartModel<sup>AI</sup>

application is measuring volumes, it is appropriate that the method looks for the largest and smallest volumes to define ED and ES, respectively, rather than rely on valve state. ED and ES are defined in HeartModel<sup>AI</sup> through a process of estimation and refinement. The ED frame is estimated as the frame corresponding to the R-peak in the ECG waveform. The ES frame is estimated by looking at the motion of the tissue in the region roughly around that of the mitral plane. This motion correlates highly to the cardiac phase. The ES frame is estimated as the frame when the tissue in this region reaches its maximum height along the transducer axis. In a comparison to a full cycle analysis, these ED and ES estimates were within one frame of the actual ED and ES in 99% of all cases studied (N=120). The ED and ES frames are refined by looking at the frames before and after the estimations and choosing the frame with the largest and smallest volume, respectively. The volumes are measured using the HeartModel<sup>AI</sup> border detection algorithm.



**Figure 4** Phase detection summary. ED is estimated as the frame at the R-peak. ES is estimated as the frame where the region around the mitral plane reaches its highest point in the volume. Both estimations are refined by looking at neighboring frames.

### Border detection

The model-based segmentation algorithm utilized in the HeartModel<sup>AI</sup> application can best be described as a sequence of pattern fitting at finer and finer spatial scales, as summarized in Figure 5.

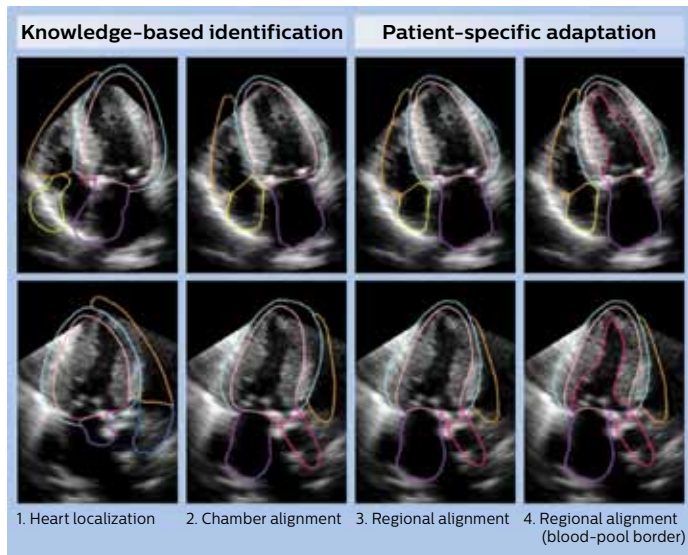
#### Knowledge-based identification

- Heart Localization:** at the coarsest scale, the general pattern of the entire heart coinciding with the shape of the model is detected in the image and the model similar to that shown in Figure 1 is then positioned, oriented, and scaled within the volume at the detected location.
- Chamber Alignment:** proceeding to a finer spatial scale, the position, orientation, and scale of each chamber in the model (LV, LA, RV, and RA) is determined and the chambers are then transformed such that each structure better aligns to the locations as seen in the image.

#### Patient-specific adaptation

- Regional alignment:** at the finest spatial scale, small localized regions within each structure are detected and the borders of the model moved to best align with the image.
- Regional alignment (blood-pool border):** as the innermost endocardial border, or blood-tissue border, exhibits a wider variation in shape as compared to the other borders, this border is initialized only after Step 3 and allowed more flexibility as compared to the other layers when locally adapting this border to best align with the image.

It is important to note that throughout the pattern fitting process, while the model is pushed and pulled to align with the image, the integrity of the model is also maintained such that the final adapted model can be considered a compromise between the patterns detected in the image and the prior knowledge imposed by the model.



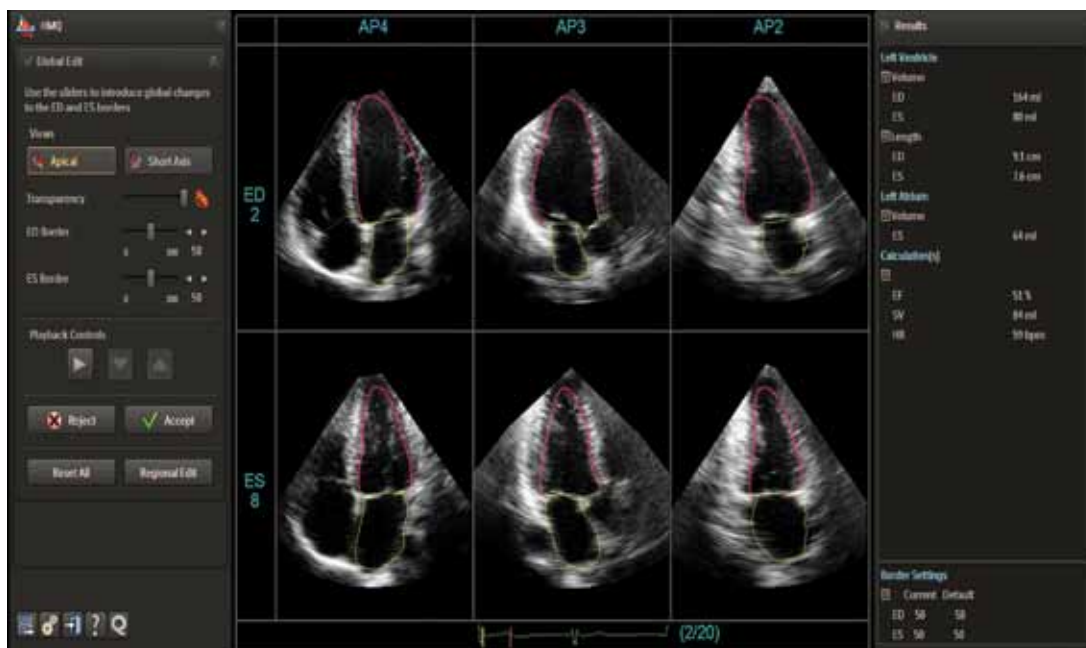
**Figure 5** A summary of the model-based segmentation algorithm designed for the HeartModel<sup>A1</sup> application. Knowledge-based identification is used to first position and orient a model of the heart in the volume, and patient-specific adaptation is used to transform gradually the model at progressively finer spatial scales to the heart as seen in the image. (Top row: AP4 view derived from 3D volume; Bottom row: AP3 view derived from 3D volume).

## Validation

The performance of HeartModel<sup>A1</sup> for the purposes of quantifying the LV at ED and ES and for quantifying the LA at left ventricular end-systole was assessed on several hundred images. In the assessments, both the inner and outer LV endocardial borders and the LA border as generated by the fully-automated HeartModel<sup>A1</sup> algorithm were compared to manual segmentations performed by several clinical experts. The analyzed images were distributed fairly evenly as far as their geographic origin (Asia, Europe, and North America), heart size, pathology, heart shape, and image quality. The HeartModel<sup>A1</sup> algorithm has also been studied at several centers globally. The results demonstrate the algorithm is very robust and accurate at adapting to a wide variety of heart sizes and shapes in images with widely varying image quality.

## Tuning and editing

In the HeartModel<sup>A1</sup> application, two LV endocardial borders are detected by the algorithm, and the onus is on the user to specify where, relative to these two borders, the final single border should be placed. This relative location is controlled in the user-interface via graphical sliders – one for ED and one for ES. The default relative location (i.e., default slider values) can be specified by the user, and may vary due to preference by an institution or user as to where borders should be placed<sup>2</sup>. This ability to tune the HeartModel<sup>A1</sup> application to meet the individual preference of users allows the HeartModel<sup>A1</sup> application to generate pertinent fully-automated or minimally-edited results despite widely varying tracing practices that exist in the clinical community.



**Figure 6** Screenshot of the HeartModel<sup>A1</sup> application 6-up display showing the automatically derived AP4 (left), AP3 (center), and AP2 (right) views for the ED (top) and ES (bottom) frames. Users can quickly adjust the location of the borders relative to the internally segmented inner and outer endocardial border using the sliders on the left of the screen.

While the borders generated by the fully-automated HeartModel<sup>A.1</sup> application will suffice in a large percentage of the cases, there will be times when editing will be necessary or desired. In those situations, the user has two editing options available: a global or regional edit. The global edit consists of adjusting the ED or ES slider value, or relative location of the single LV endocardial border relative to the inner and outer borders that were automatically detected by the algorithm. Regional editing involves the user adjusting the border on a more localized basis via control points placed along the contour. The regional editing allows the user to use the HeartModel<sup>A.1</sup> application even on hearts exhibiting a very unique or irregular shape.

The visualization and editing interface designed in the HeartModel<sup>A.1</sup> application automatically displays the standard AP2, AP3, and AP4 views. The positions and orientations of the views relative to the 3D volume are derived from the segmented model. This is a time-saving operation as compared to other methods that require manual orientation of these views. These views are automatically adjusted to the LV or LA at the press of a button so the chamber of interest is not foreshortened. In doing so, ultrasound users are not required to have significant experience in navigating around 3D ultrasound volumes, but are rather automatically shown images derived from the volume that are typically acquired in a routine ultrasound exam and which users are accustomed to viewing and analyzing.

## Conclusion

The Philips HeartModel<sup>A.1</sup> application is a fully-automated model-based segmentation method for LV and LA measurement designed to address the variability inherent in current clinical practice. As opposed to detecting a single border, the HeartModel<sup>A.1</sup> algorithm detects two endocardial borders – one at the blood-tissue interface and another at the compacted myocardium – and from these, allows the user to specify a single endocardial border to meet their clinical judgement or practice. As the two detected borders are easily and robustly identified in an image, the resulting single endocardial border identified by the user is both accurate and robust across a wide range of heart shapes and image quality. Coupling the sophisticated segmentation algorithms with an intuitive workflow and user interface that provides quick and easy visualization and editing, the HeartModel<sup>A.1</sup> application enables confident routine clinical use of 3D ultrasound images.

## References

1. Lang, Roberto M, et al. "Recommendations for Cardiac Chamber Quantification by Echocardiography in Adults: An Update from the American Society of Echocardiography and the European Association of Cardiovascular Imaging." *Journal of the American Society of Echocardiography* 28.1 (2015): 1-39.
2. Dorosz, Jennifer L, et al. "Performance of 3-dimensional echocardiography in measuring left ventricular volumes and ejection fraction: a systematic review and meta-analysis." *Journal of the American College of Cardiology* 59.20 (2012): 1799-1808.

© 2015 Koninklijke Philips N.V. All rights are reserved.

Philips Healthcare reserves the right to make changes in specifications and/or to discontinue any product at any time without notice or obligation and will not be liable for any consequences resulting from the use of this publication.



Please visit [www.philips.com](http://www.philips.com)

Printed in The Netherlands.  
4522 991 11691 \* JUN 2015